

Cardiac Magnetic Resonance Assessment of Myocarditis

Xiaohai Ma M.D, PhD

Beijing Anzhen Hospital, Capital Medical University

Disclosure: none



Original Investigations Regarding to Myocarditis



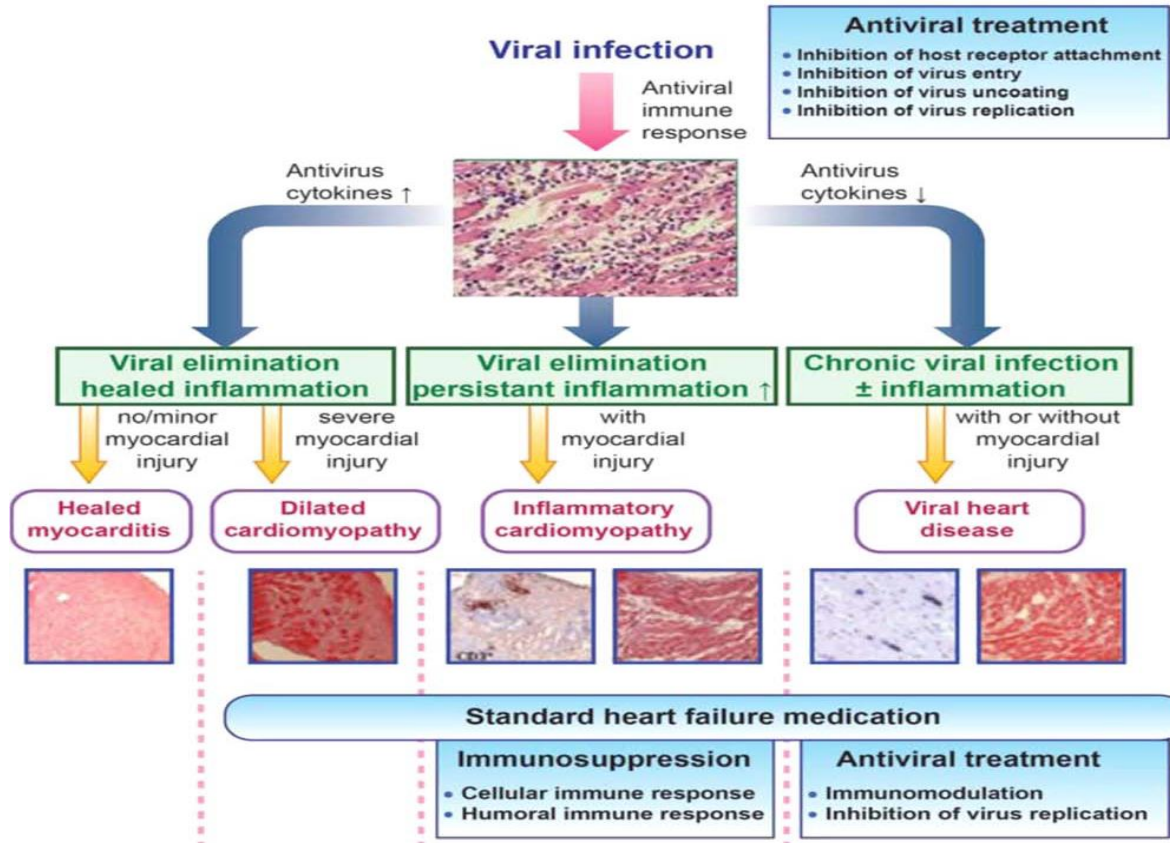
Journals	Papers of myocarditis	Recent 10 yrs papers
NEJM	147	29
JAMA	45	1
EHJ	283	129
JACC	227	103

Issues of Myocarditis Diagnosis



- Studies addressing the issue of sudden cardiac death in young people report a highly variable autopsy prevalence of myocarditis, ranging from 2 to 42% of cases
- Myocarditis is a challenging diagnosis due to the heterogeneity of clinical presentations
- The actual incidence of myocarditis is also difficult to determine as EMB, the diagnostic gold standard, is used infrequently
- 2013 Position Statement of the European Society of Cardiology Working Group on Myocardial and Pericardial Diseases

Pathogenetic mechanisms involved in myocarditis and progression to DCM



2013 Position Statement of the ESC Working Group on Myocardial and Pericardial Diseases

Definitions

Myocarditis (WHO /ISFC¹):

Inflammatory disease of the myocardium diagnosed by established histological, immunological and immunohistochemical criteria**.*

**N.B. established histological Dallas criteria¹² defined as follows:*

'histological evidence of inflammatory infiltrates within the myocardium associated with myocyte degeneration and necrosis of non-ischaemic origin¹².'

***N.B. unspecified immunohistochemical criteria¹, we propose an abnormal inflammatory infiltrate to be defined as follows:*

' ≥ 14 leucocytes/mm² including up to 4 monocytes/mm² with the presence of CD 3 positive T-lymphocytes ≥ 7 cells/mm².'^{15,18,19}

Inflammatory Cardiomyopathy (WHO /ISFC¹):

Myocarditis in association with cardiac dysfunction.

N.B. Inflammatory cardiomyopathy, involved in the pathogenesis of DCM, includes idiopathic, autoimmune and infectious subtypes.¹

Dilated Cardiomyopathy (ESC¹³; WHO /ISFC¹):

DCM is a clinical diagnosis characterized by dilation and impaired contraction of the left or both ventricles that is not explained by abnormal loading conditions or coronary artery disease.

N.B. DCM includes idiopathic, familial/genetic, viral and/or immune, alcoholic/toxic subtypes.¹

2013 Position Statement of the ESC Working Group on Myocardial and Pericardial Diseases

Table 4 Diagnostic criteria for clinically suspected myocarditis

Clinical presentations^a

Acute chest pain, pericarditic, or pseudo-ischaemic

New-onset (days up to 3 months) or worsening of: dyspnoea at rest or exercise, and/or fatigue, with or without left and/or right heart failure signs

Subacute/chronic (> 3 months) or worsening of: dyspnoea at rest or exercise, and/or fatigue, with or without left and/or right heart failure signs

Palpitation, and/or unexplained arrhythmia symptoms and/or syncope, and/or aborted sudden cardiac death

Unexplained cardiogenic shock

Diagnostic criteria

I. ECG/Holter/stress test features

Newly abnormal 12 lead ECG and/or Holter and/or stress testing, any of the following: I to III degree atrioventricular block, or bundle branch block, ST/T wave change (ST elevation or non ST elevation, T wave inversion), sinus arrest, ventricular tachycardia or fibrillation and asystole, atrial fibrillation, reduced R wave height, intraventricular conduction delay (widened QRS complex), abnormal Q waves, low voltage, frequent premature beats, supraventricular tachycardia

II. Myocardiocytolysis markers

Elevated TnT/TnI

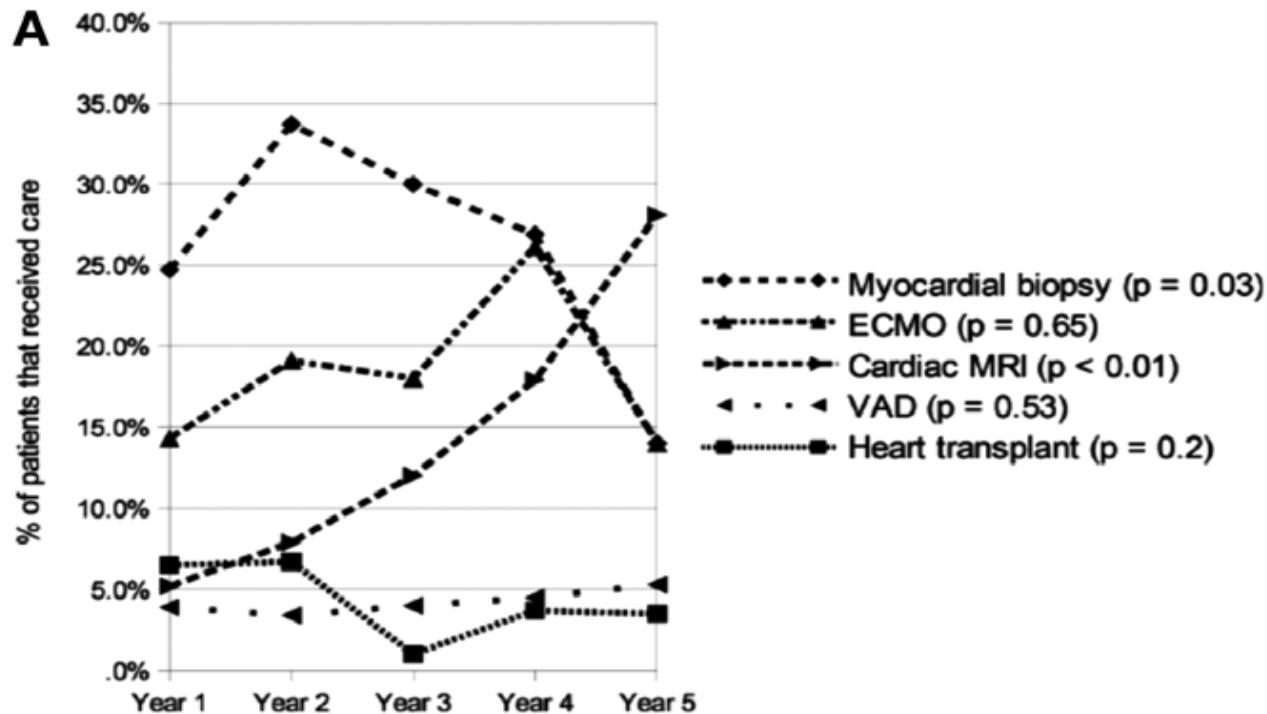
III. Functional and structural abnormalities on cardiac imaging (echo/angio/CMR)

New, otherwise unexplained LV and/or RV structure and function abnormality (including incidental finding in apparently asymptomatic subjects): regional wall motion or global systolic or diastolic function abnormality, with or without ventricular dilatation, with or without increased wall thickness, with or without pericardial effusion, with or without endocavitary thrombi

IV. Tissue characterization by CMR

Oedema and/or LGE of classical myocarditic pattern (see text)

Temporal trends in use of diagnostic modalities in pediatric myocarditis in the US



Proposed diagnostic CMR criteria (Lake Louise Consensus Criteria) for myocarditis

In the setting of clinically suspected myocarditis^a, CMR findings are consistent with myocardial inflammation, if at least two of the following criteria are present:

- 1 Regional or global myocardial SI increase in T2-weighted images^b. □
- 2 Increased global myocardial early gadolinium enhancement ratio between myocardium and skeletal muscle in gadolinium-enhanced T1-weighted images^c. □
- 3 There is at least one focal lesion with non-ischemic regional distribution in IR-prepared gadolinium-enhanced T1-weighted images ("late gadolinium enhancement")^d.

A CMR study is consistent with myocyte injury and/or scar caused by myocardial inflammation, if

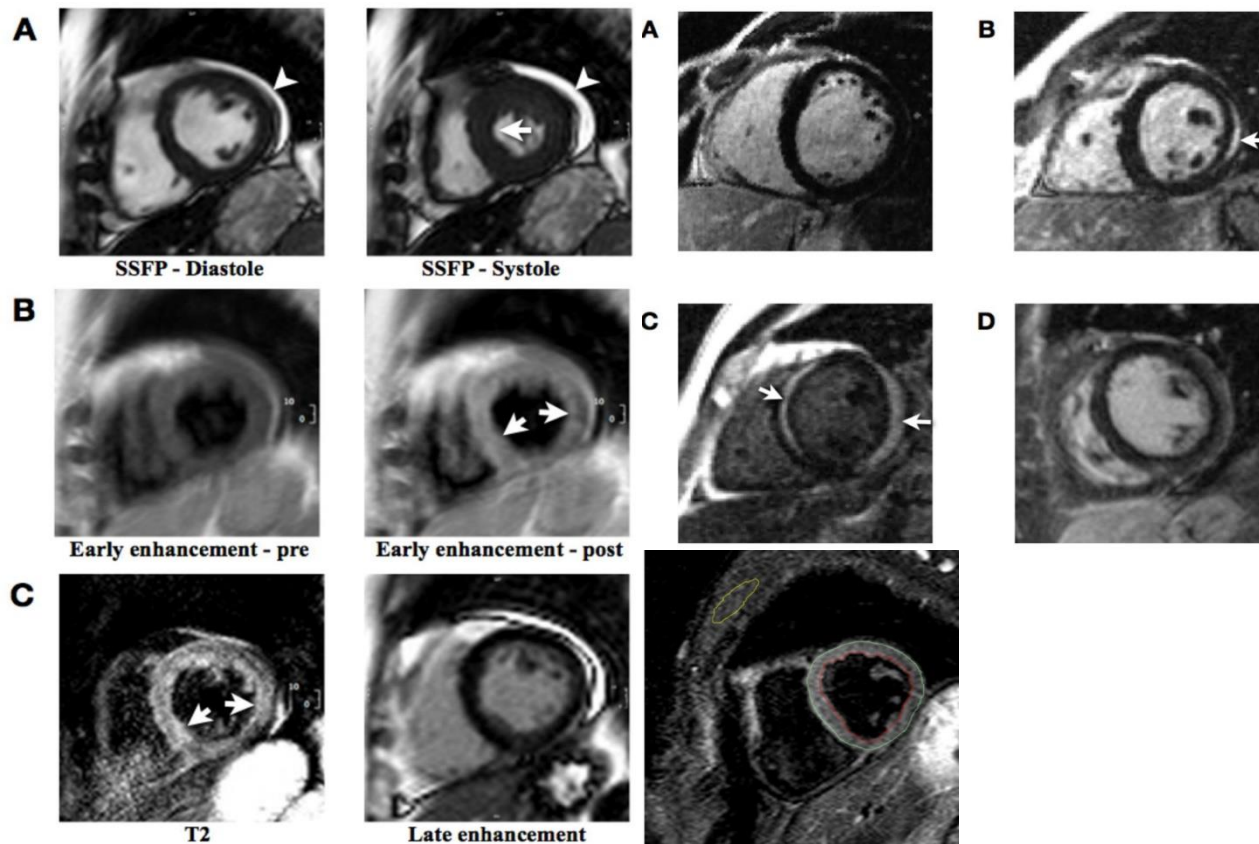
- criterion 3 is present.

A repeat CMR study between 1 and 2 weeks after the initial CMR study is recommended, if

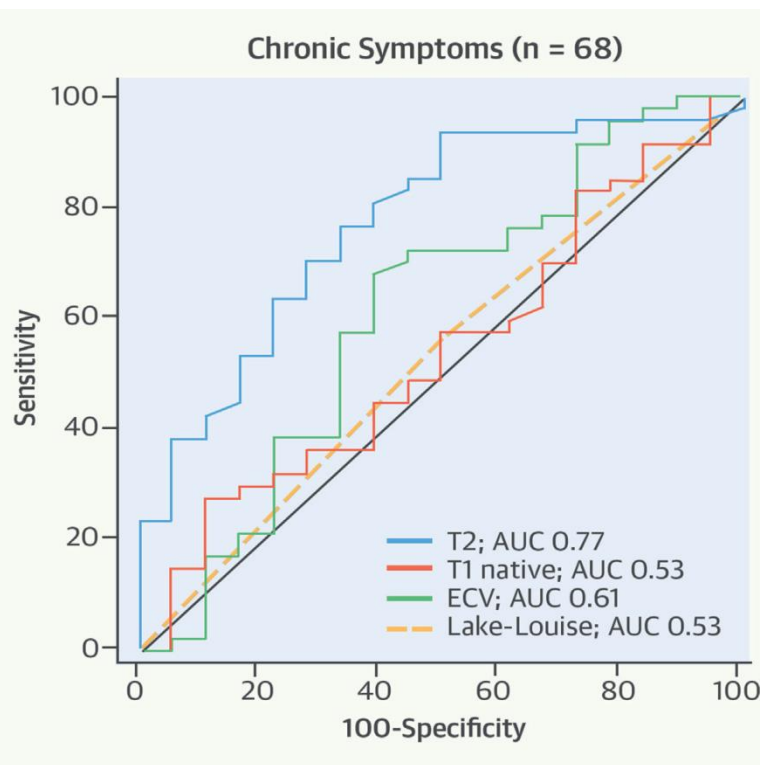
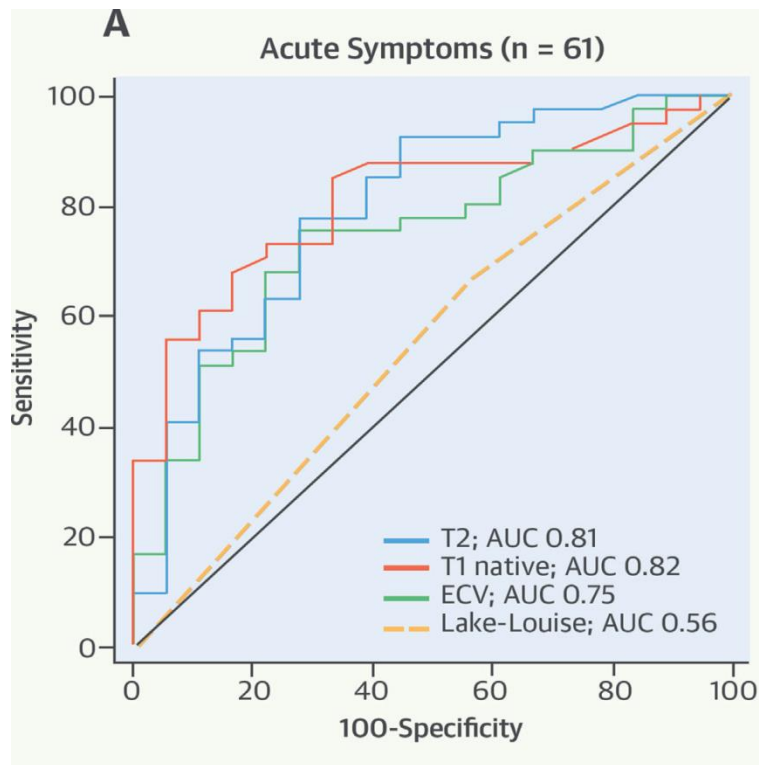
- none of the criteria are present, but the onset of symptoms has been very recent and there is strong clinical evidence for myocardial inflammation.
- one of the criteria is present.

The presence of LV dysfunction or pericardial effusion provides additional, supportive evidence for myocarditis.

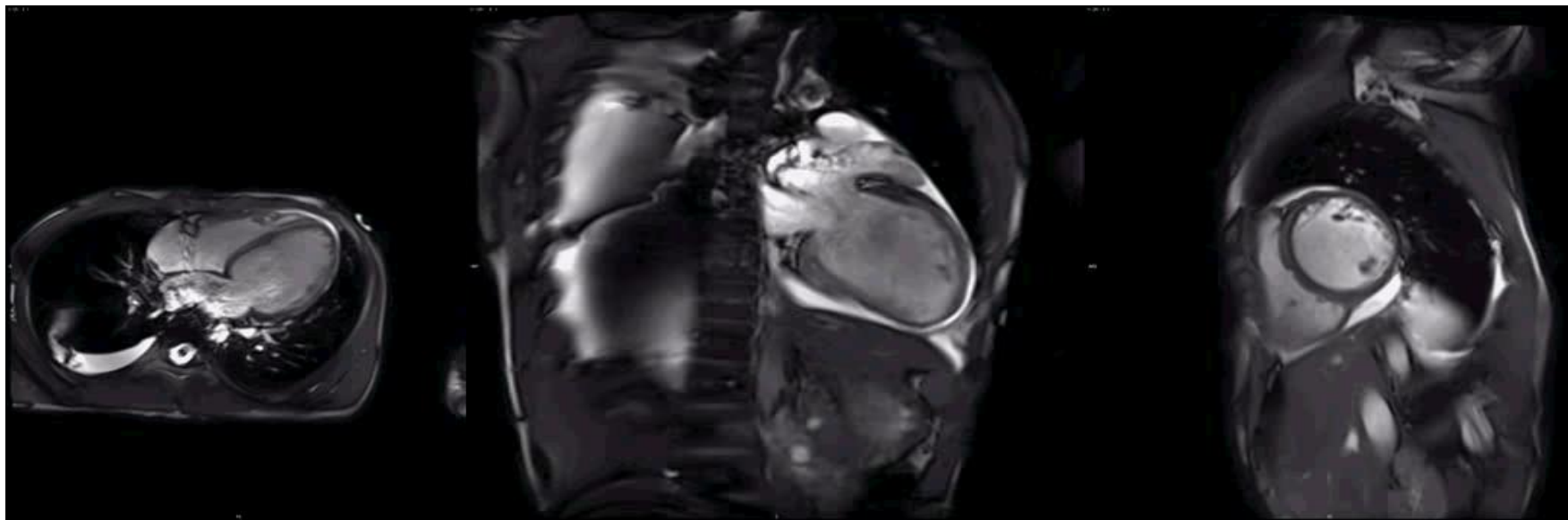
What CMR can do



CMR mapping for myocarditis



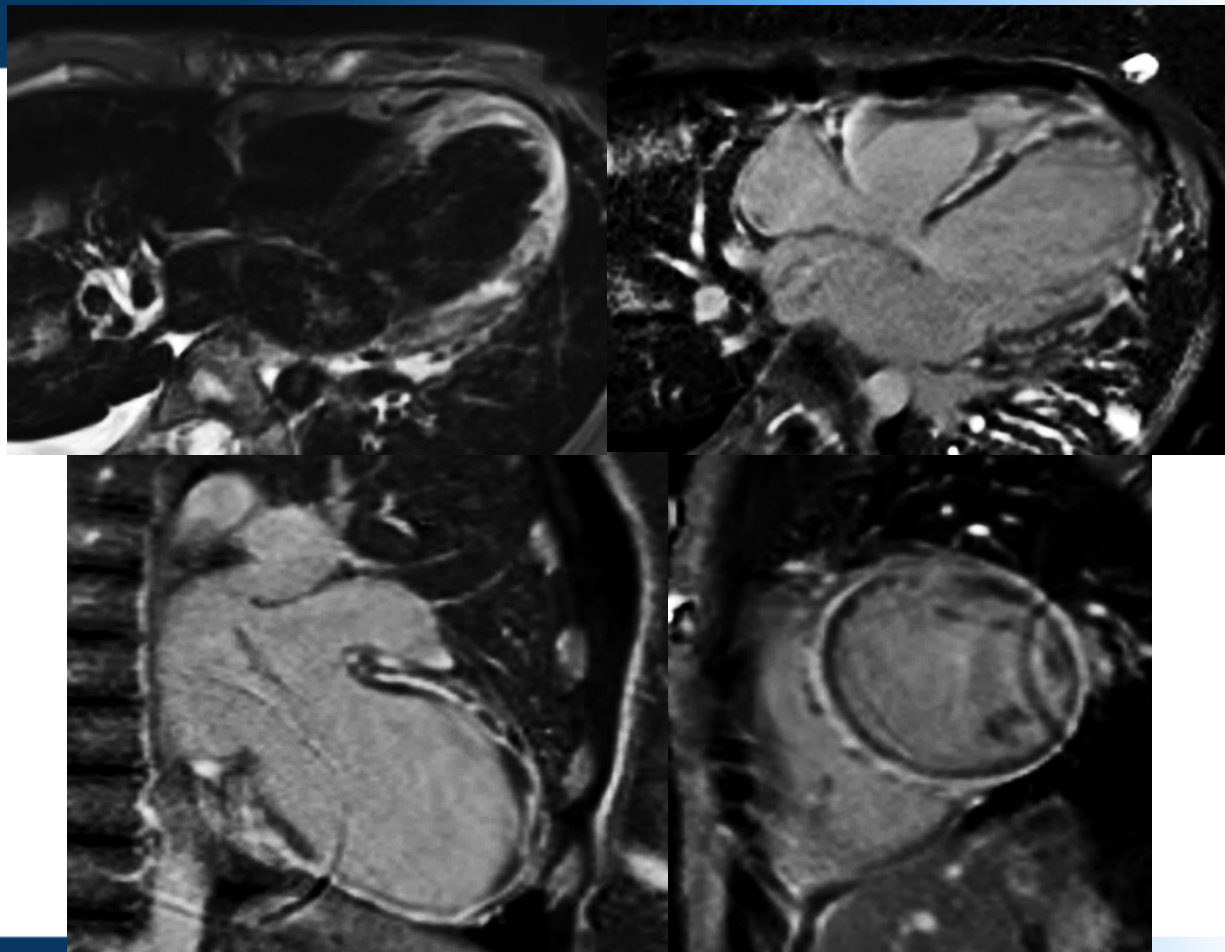
QUICKLY CASES SHOW

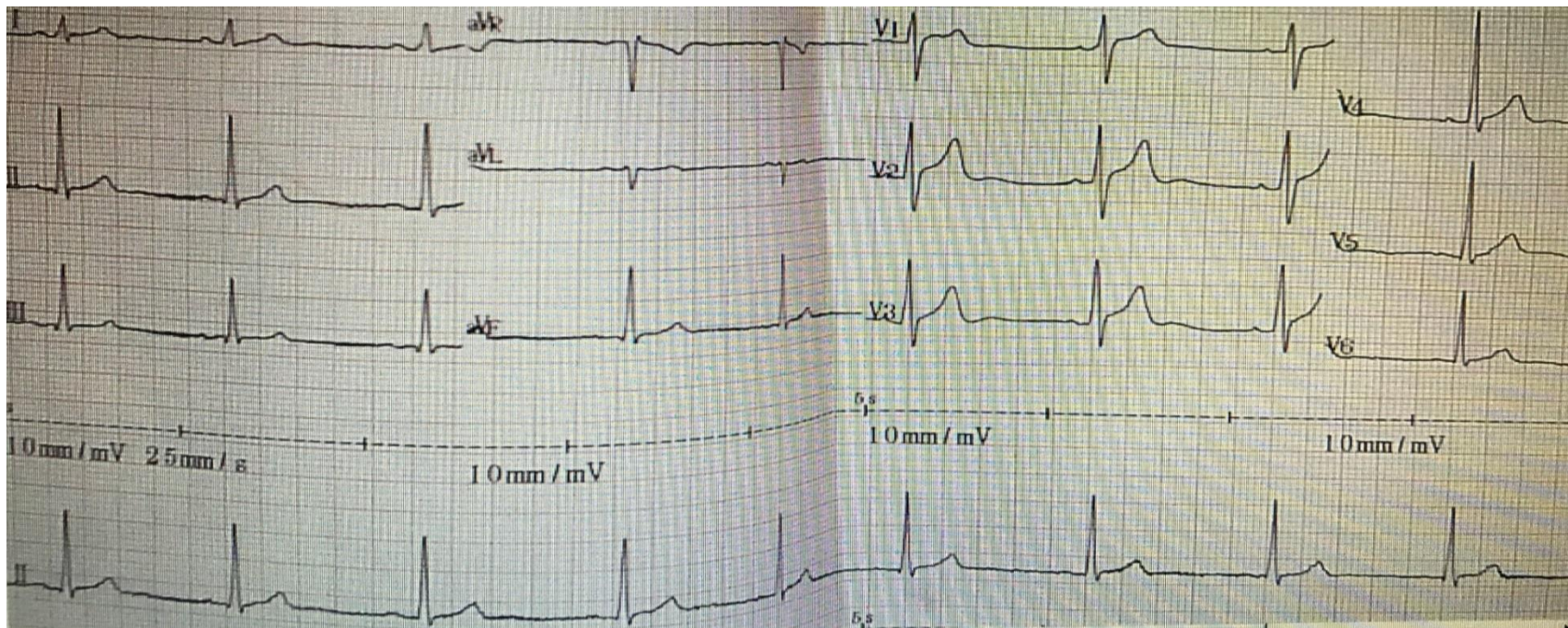


M/14 , CC: chest distress for 20 d, EF: 12%

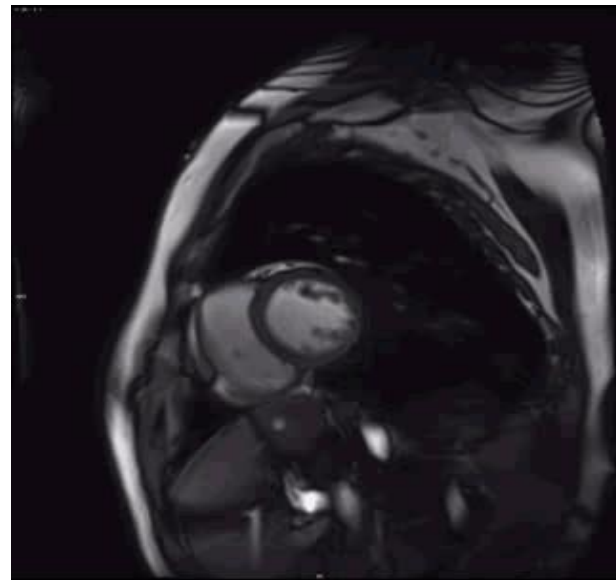
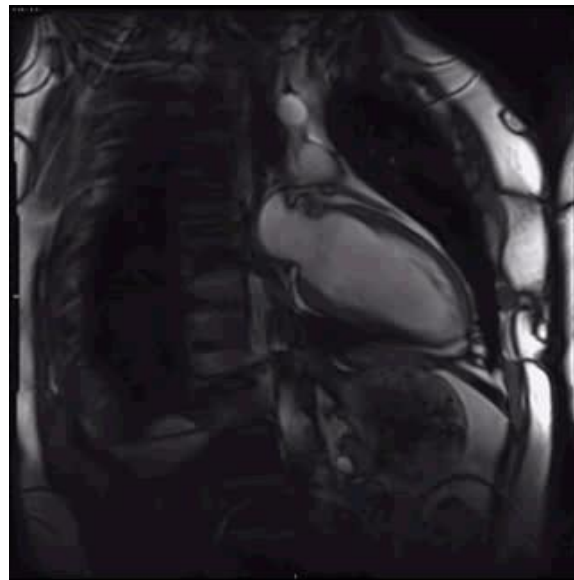
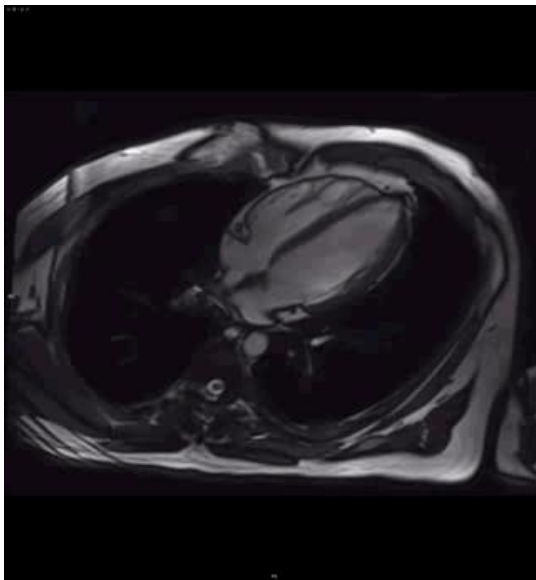


安贞医院
ANZHEN HOSPITAL





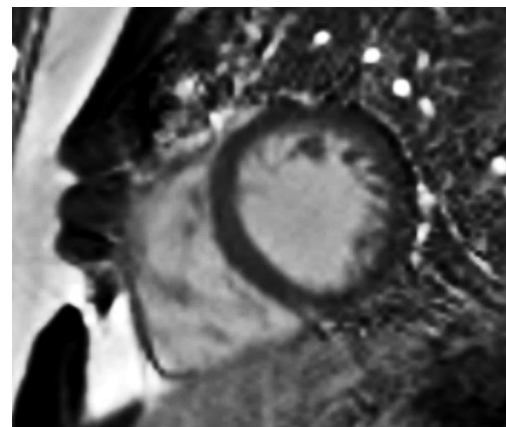
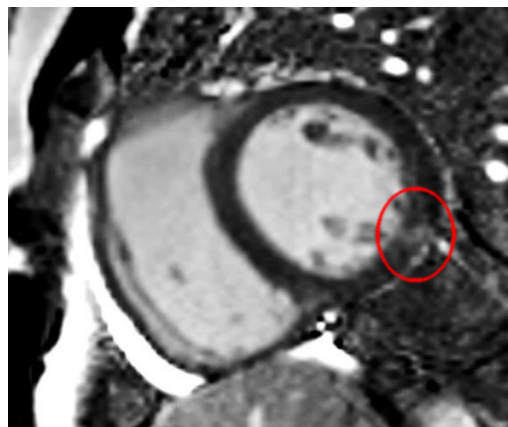
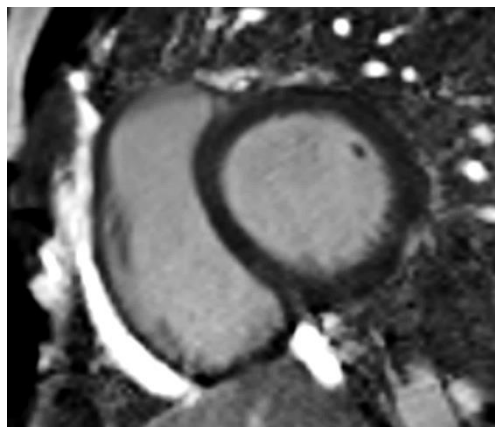
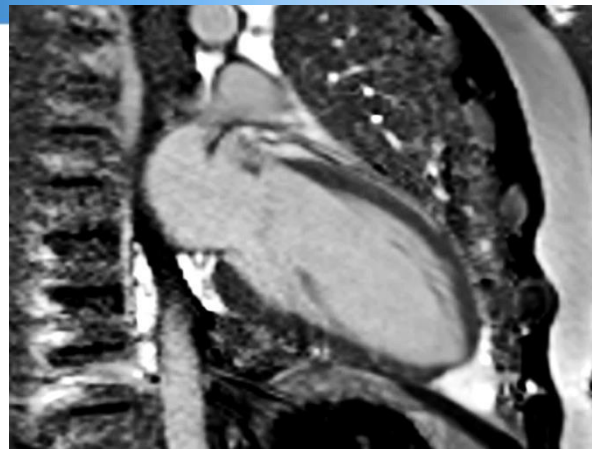
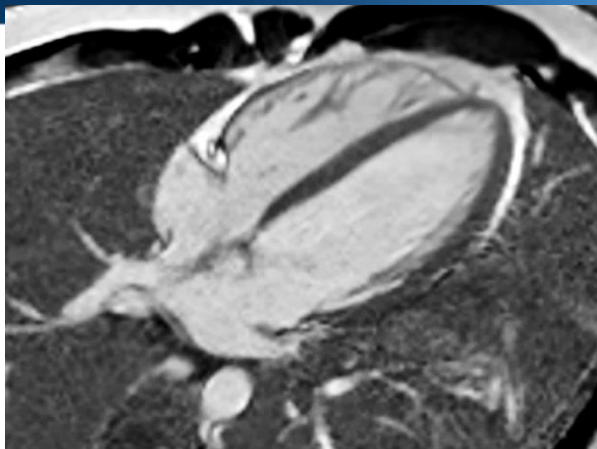
M/20Y , Dx : myocarditis , heart failure

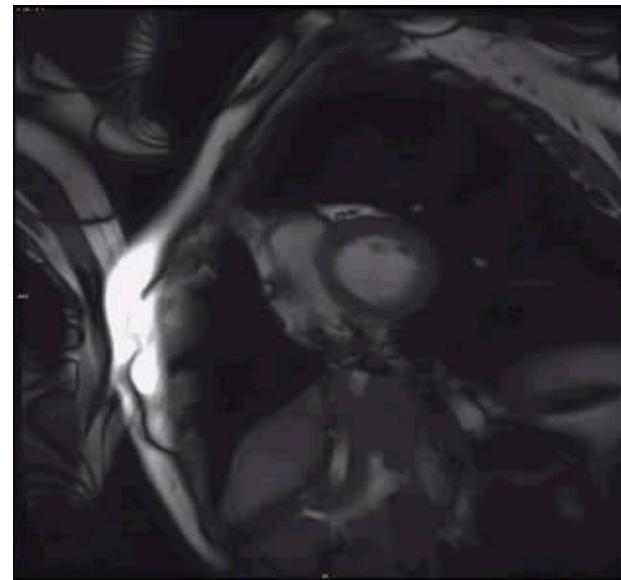
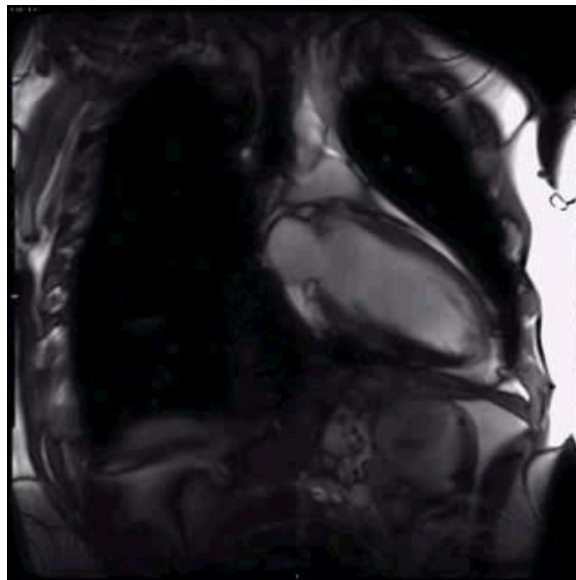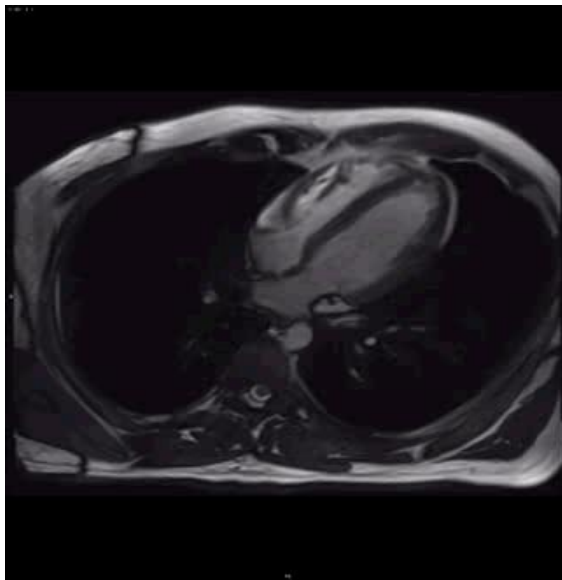


2015.9.23 EF: 47%

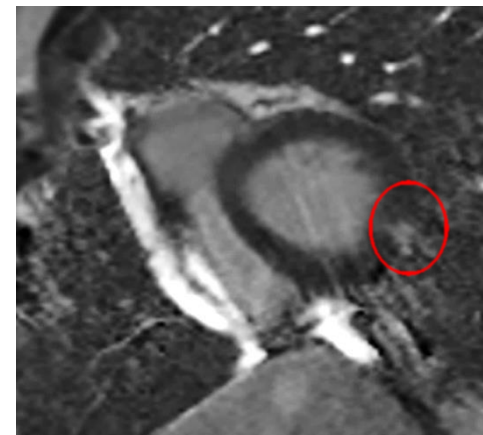
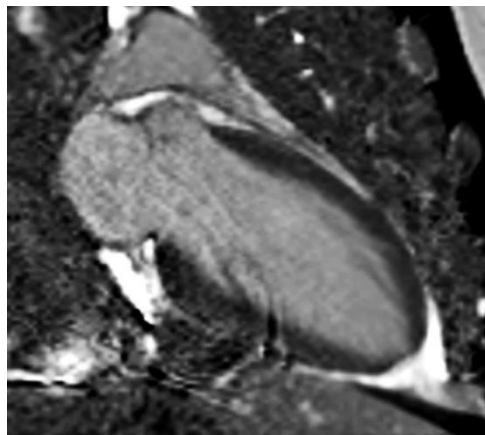
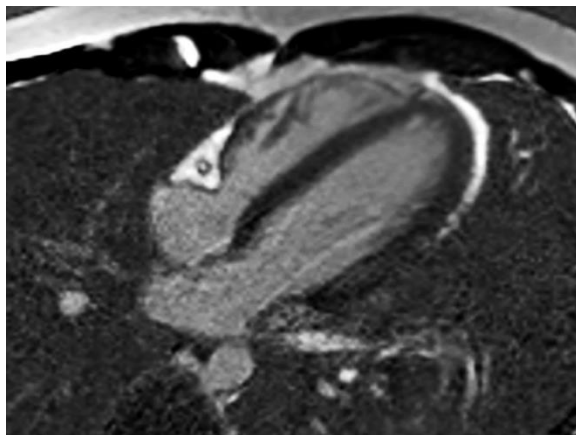


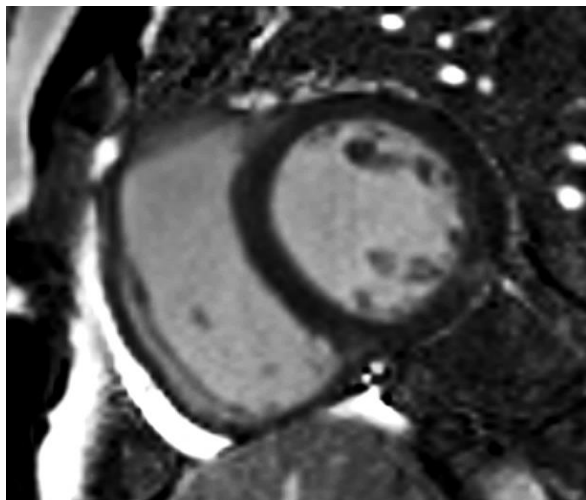
安贞医院
ANZHEN HOSPITAL



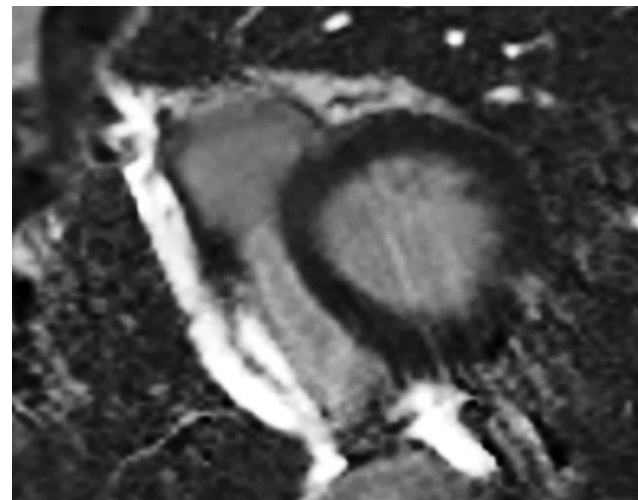


2016.2.16 EF: 60%

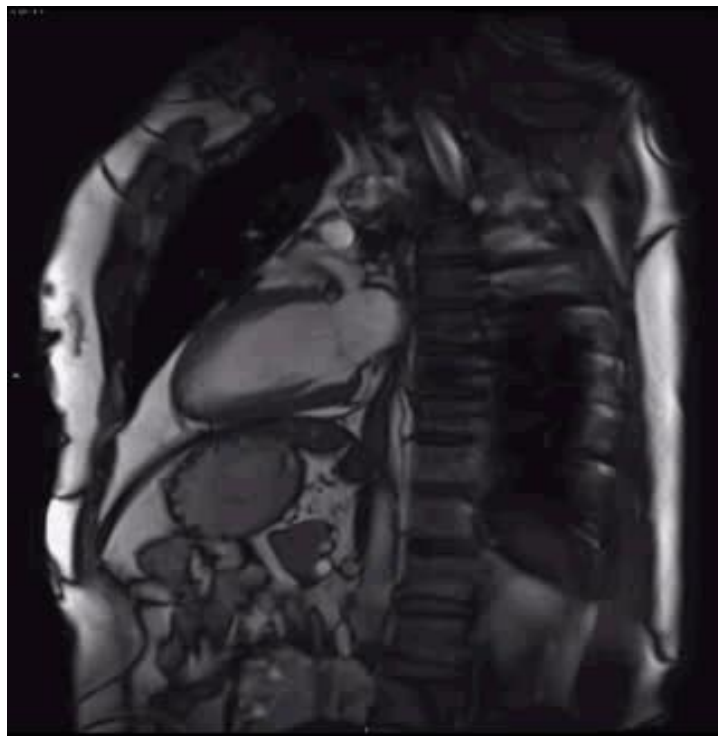
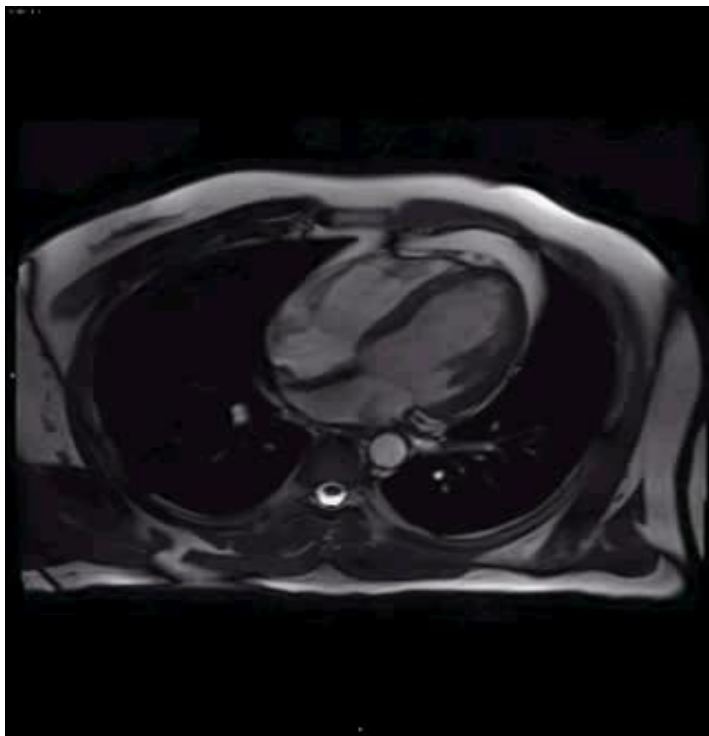




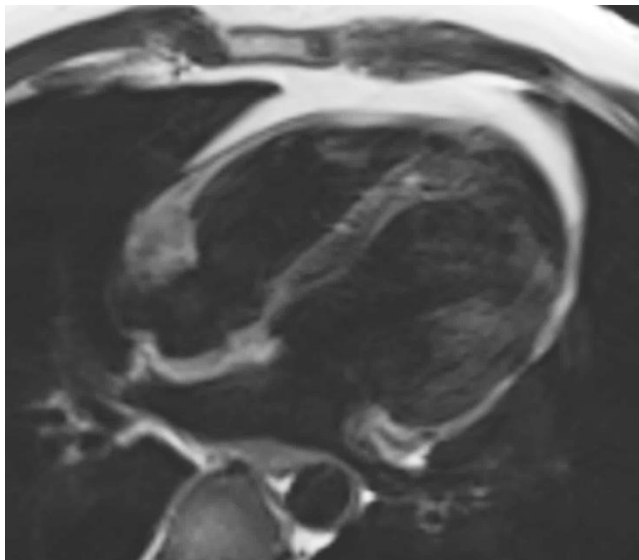
2015.9.23



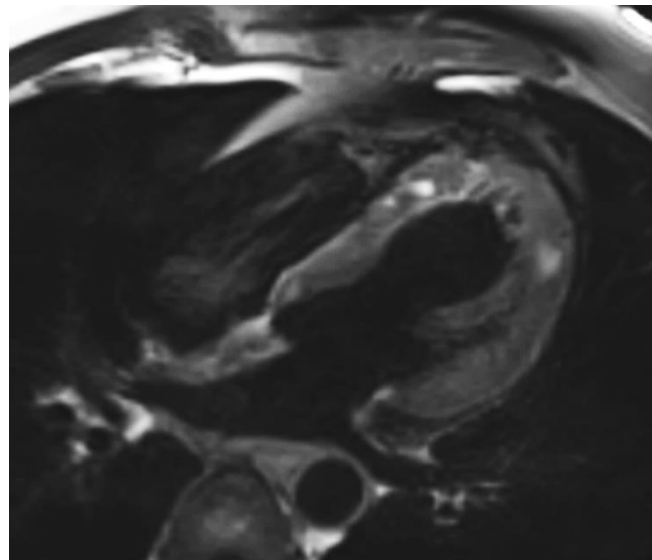
2016.2.16



M/30Y , CC : chest distress , suspected of myocarditis
2015.11.26



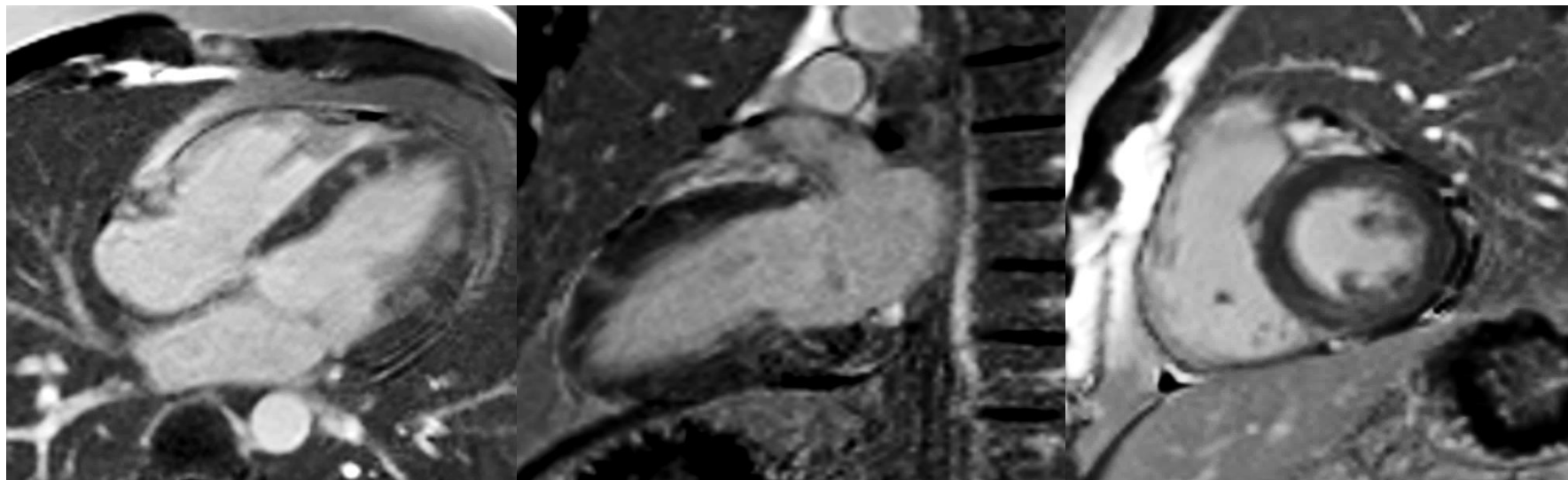
T2WI

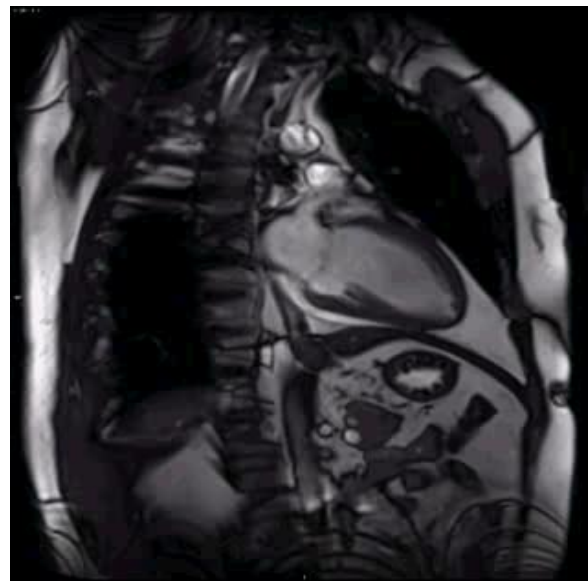
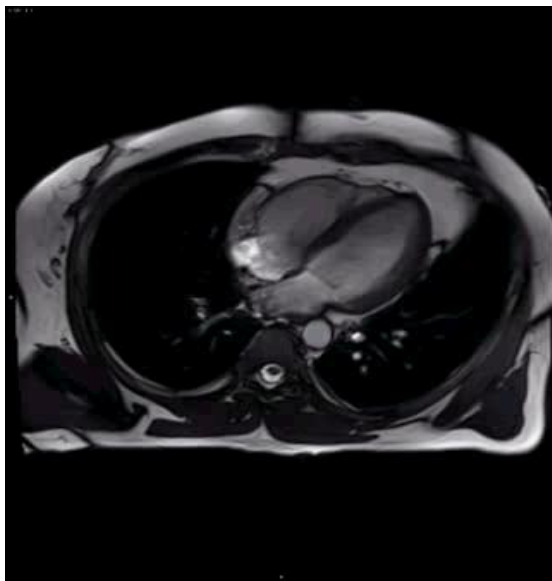


T2WI+FS



安贞医院
ANZHEN HOSPITAL

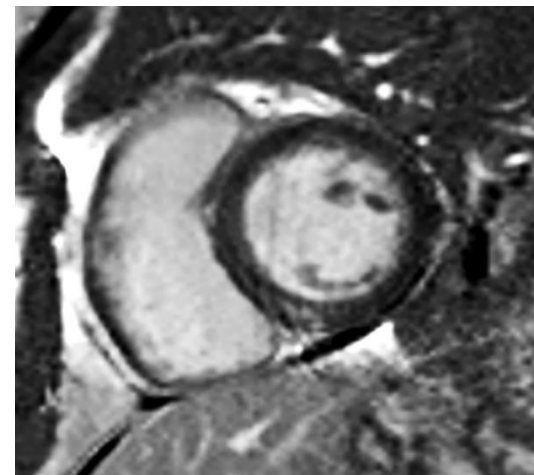
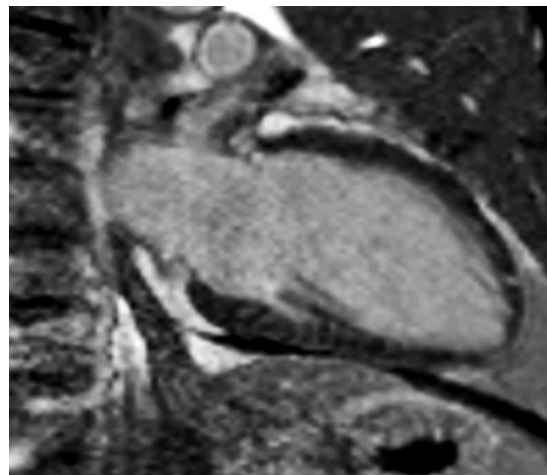
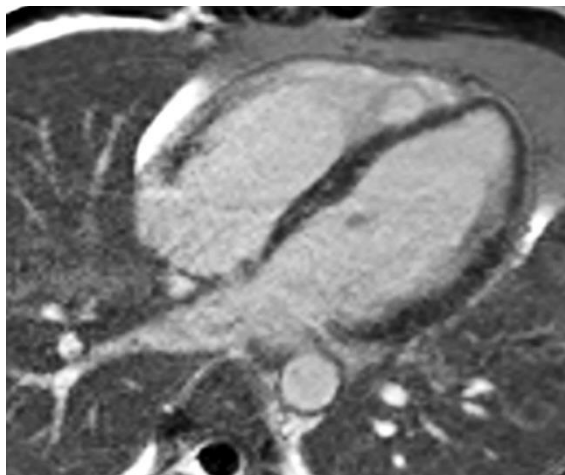


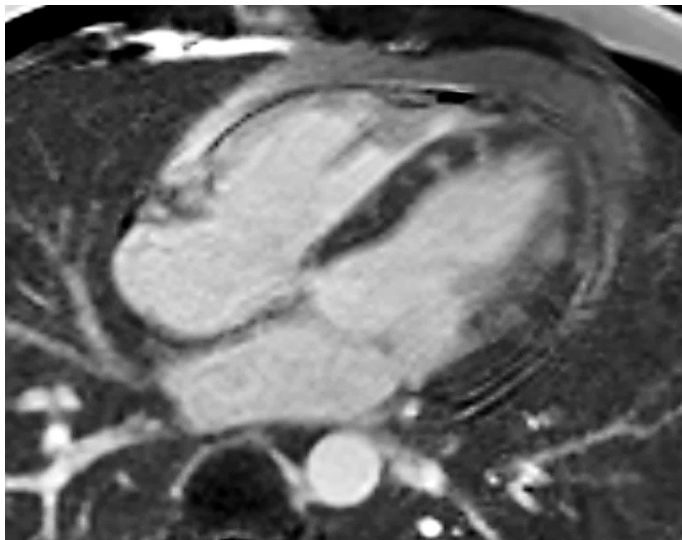


2016.6.16

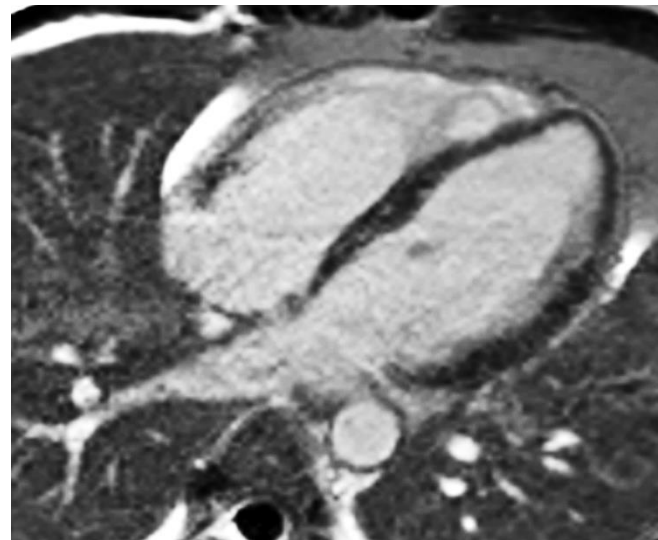


安贞医院
ANZHEN HOSPITAL

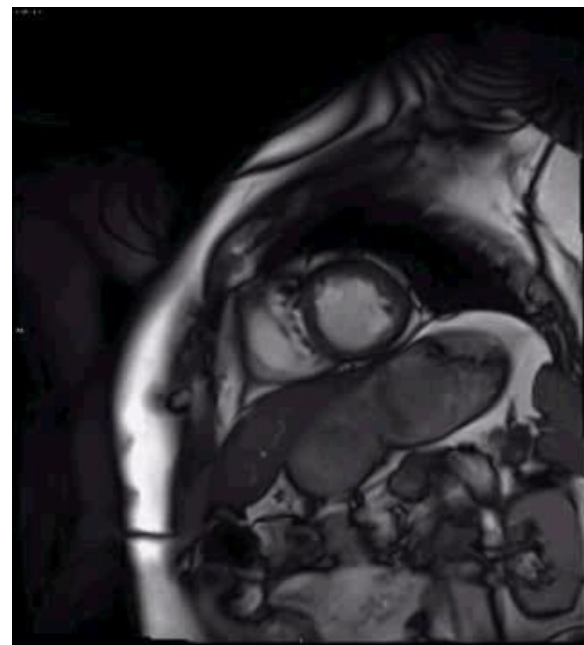
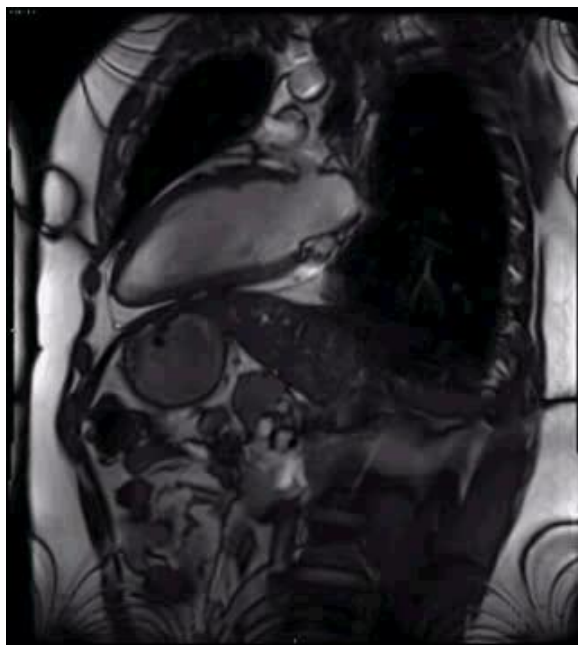
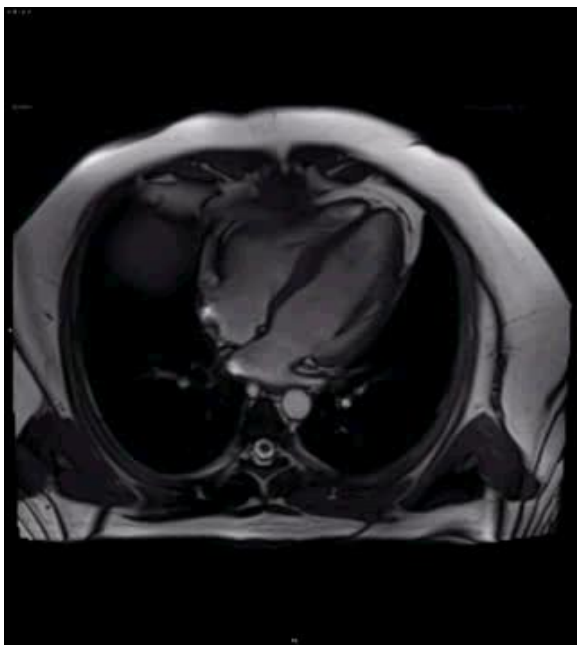


2015.11.26



2016.6.16

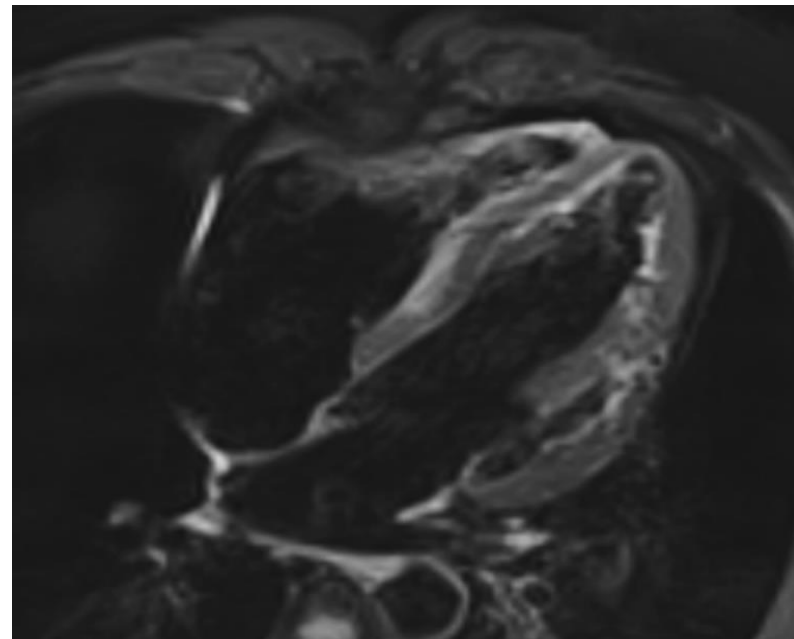
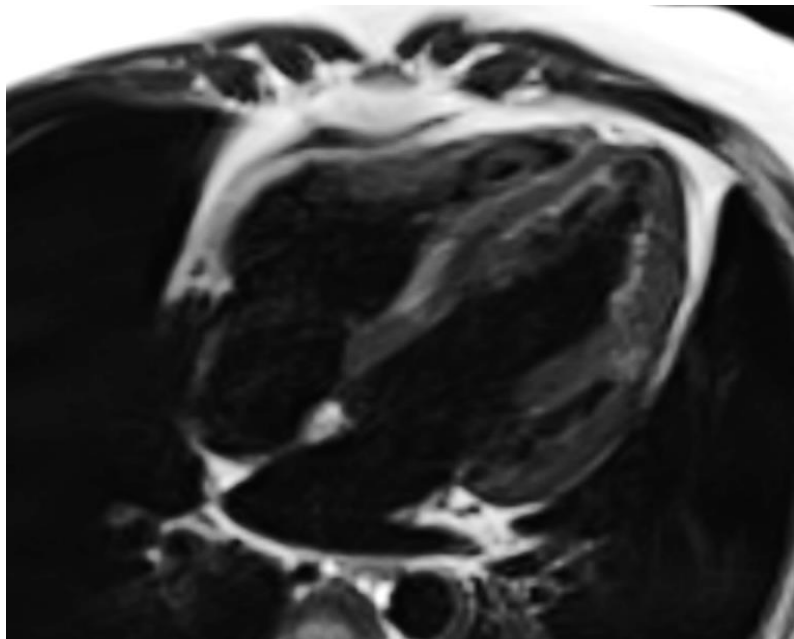


M/23Y , CC : chest pain, syncope, VT
2017.3.21

Lei Zhao, Cardiovasc Diagn Ther 2019;9(2):189-193

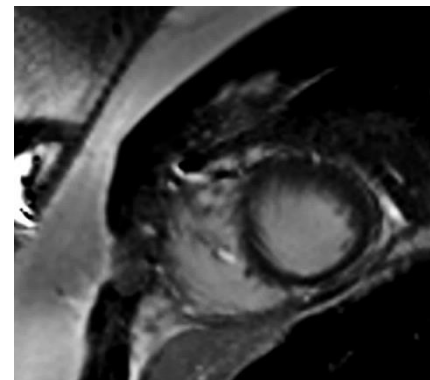
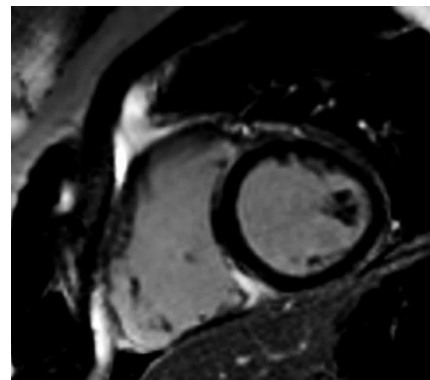
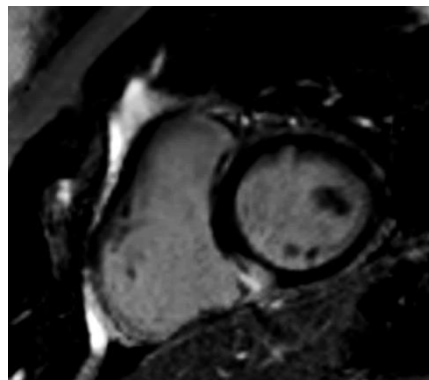
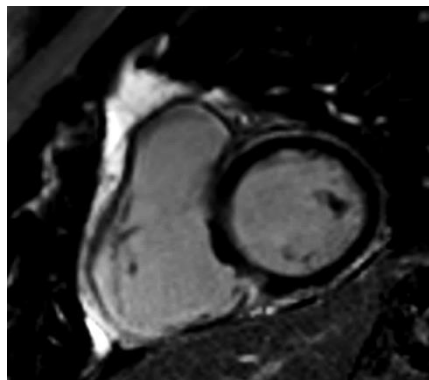
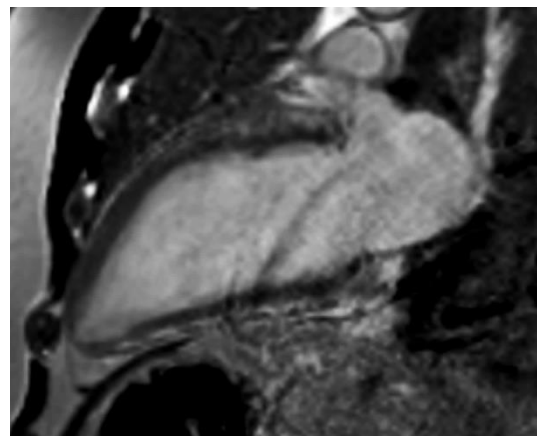
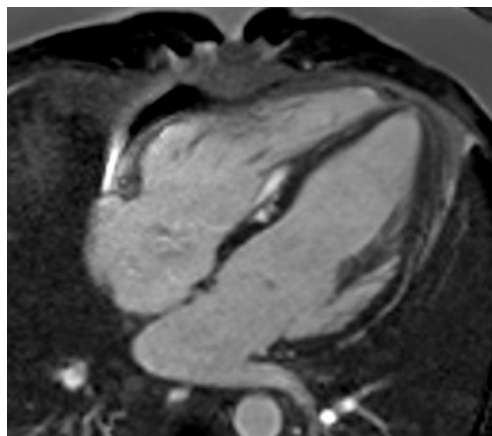


安贞医院
ANZHEN HOSPITAL

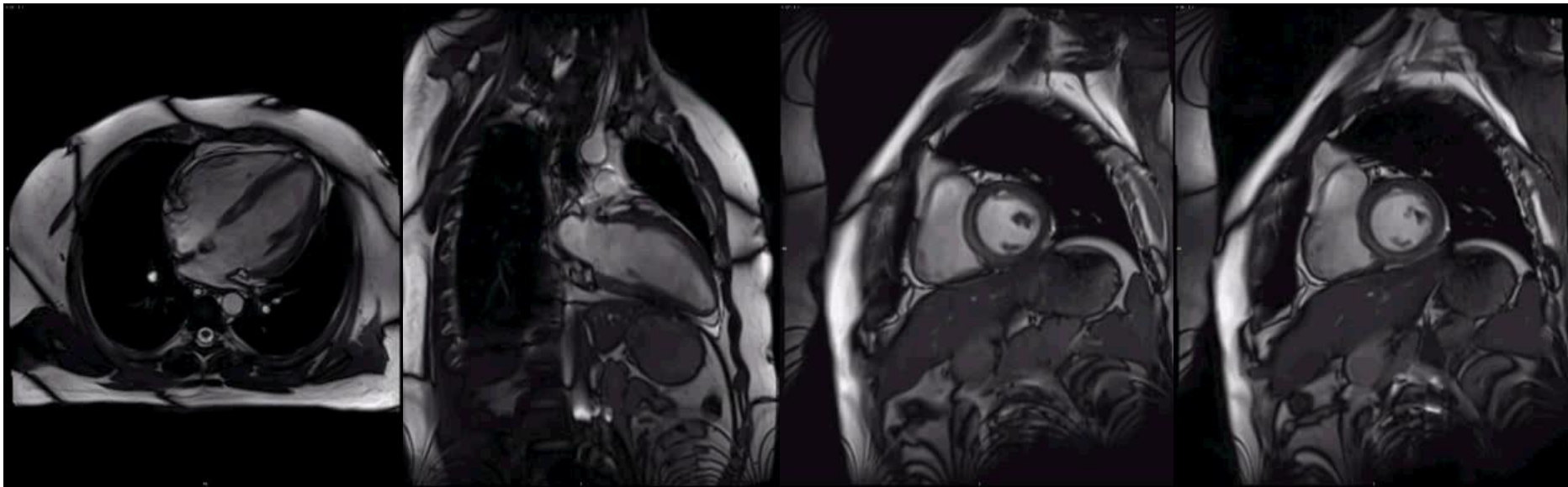




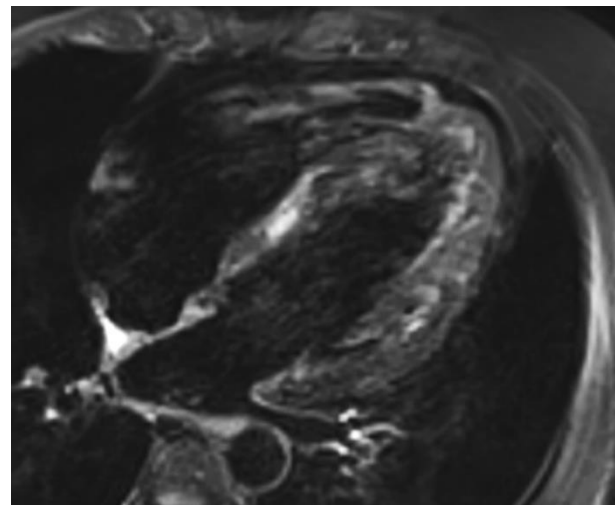
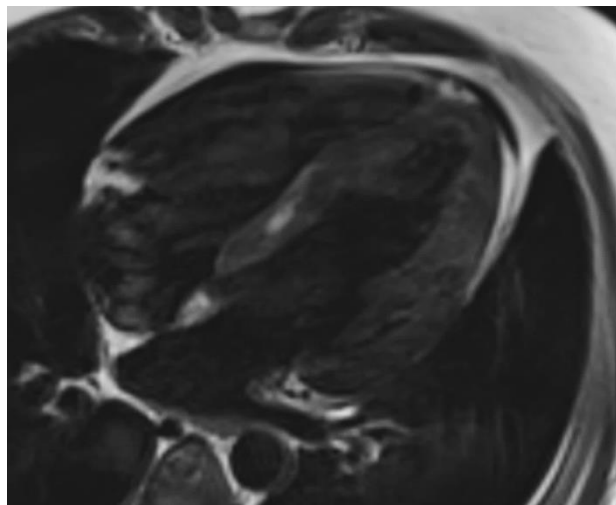
安贞医院
ANZHEN HOSPITAL



- the patient complained about sudden acute chest distress and nausea during hospital
- TnI, CKMB, MYO were significantly elevated then, **TPO Ab and TgAb increased!**
- iv. methylprednisolone (200 mg/Qd) and immunoglobulin (10 mg/Qd) was given for 5 days
- 3 days after therapy, TnIs were nearly back to normal, the patient's symptoms resolved

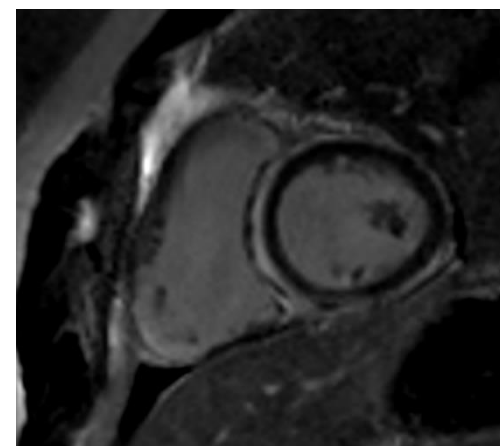
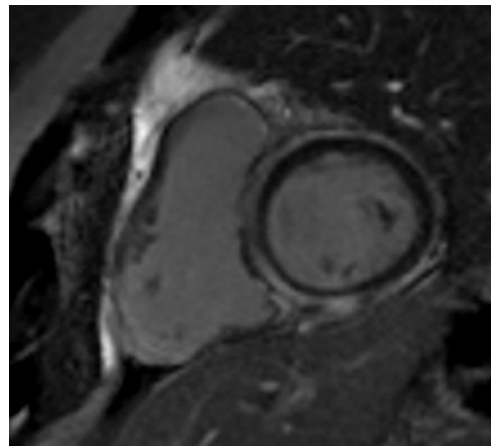
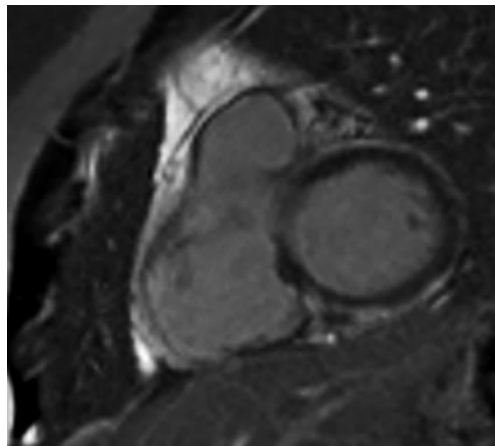
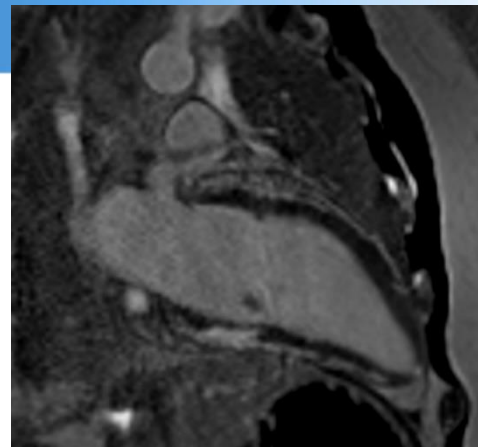
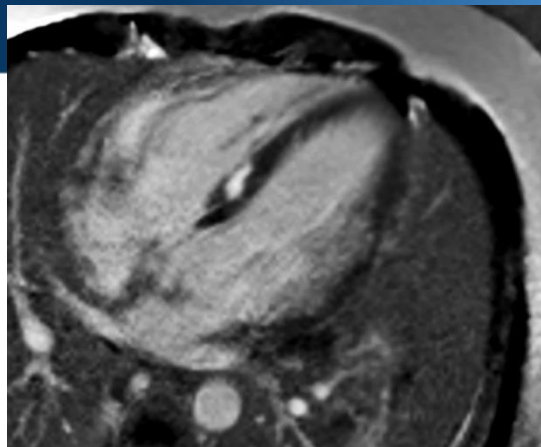


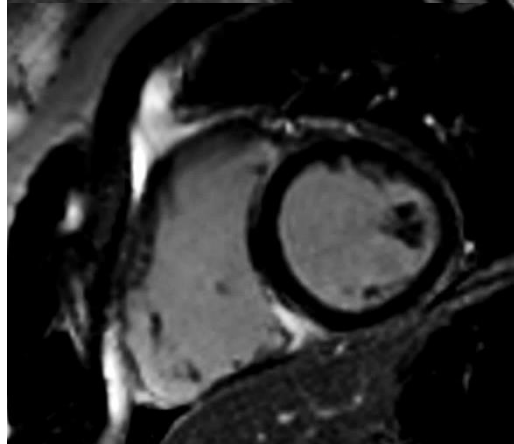
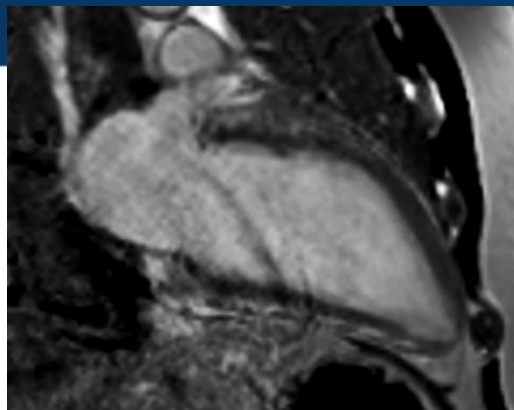
Repeat CMR 2017.3.29



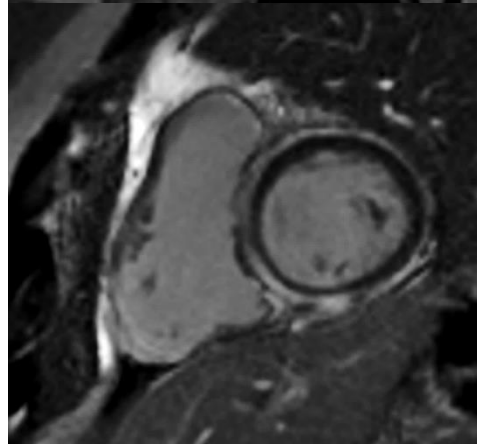
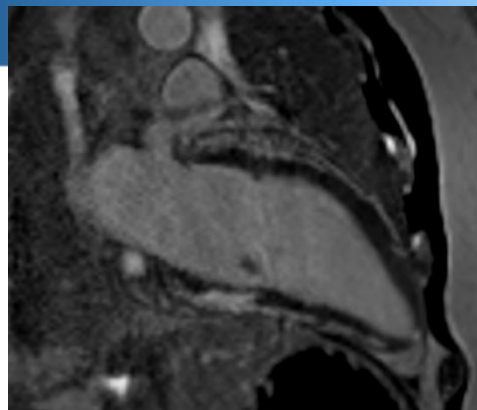


安贞医院
ANZHEN HOSPITAL





2017.3.21



2017.3.29

The symptom disappeared and lab results normalized, but imaging evidence of myocardial injury persisted!

Final Diagnosis
Autoimmunity
Myocarditis

- CMR provides non-invasive tissue characterization of the myocardium and can support the diagnosis of myocarditis
- CMR appears suitable to identify patients with significant ongoing inflammation
- Comprehensive CMR protocol to determine extent and regional distribution of reversible and irreversible myocardial injury

THANK YOU!

